

Troubleshooting to success

Mihai Cocoi- Cluj-Napoca, Romania

Maksymilian Opolski- Warsaw, Poland

! DUE TO ON-LINE UPLOAD PPT FILE SIZE LIMITS, THIS PRESENTATION DOES NOT CONTAIN ALL SLIDES AND VIDEOS.

Male, 48 yo

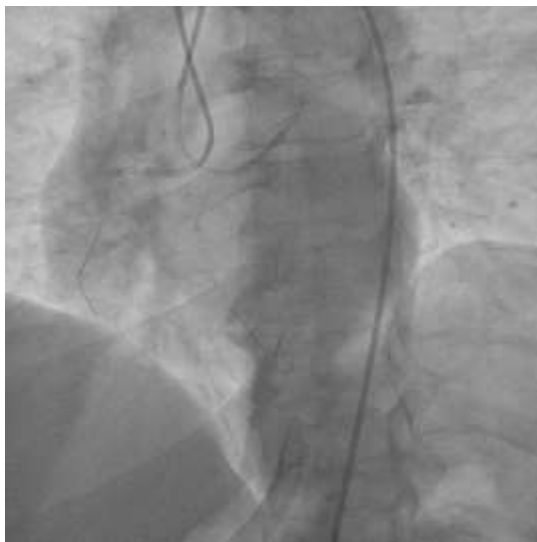Complaints: CCS 2 stable angina (since 2020)- persistent on OMT

Nov 2021:

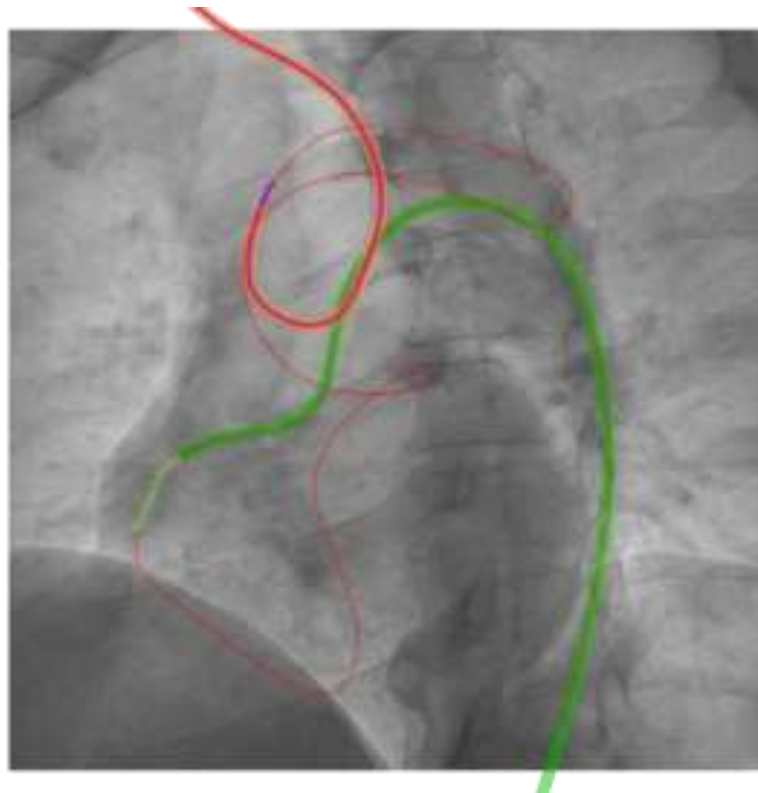
- **Coronary angio: one vessel disease (CTO of mid-distal RCA, JCTO score=2 due to blunt cap and length).**
- **Another operator: attempt of the RCA CTO= failed (AWE only)**

July 2023:

- **Retry of the RCA CTO, JCTO score=3**
- **No significant ecg abnormalities**
- **LVEF=50%**
- **Hg and Cr= normal range**



- Blunt proximal cap
 - Lesion length: 30 mm
 - Normal tortuosity
 - Minimal calcium
 - Retry PCI
 - JCTO score=3
 - Bifurcation after the distal cap
-
- Plan:
 1. AWE/prox cap prep
 2. Retro
 3. Bailout DR



- Advanced wire in antegrade guiding and followed with MC
- Did RCART after 3 h of trying to connect
- Decided to use externalisation wire
- And then...

Patient

