

Balloon trapped and vessel perf! What else???

Dr Damien Broucqsault

Dr Marine Baijot

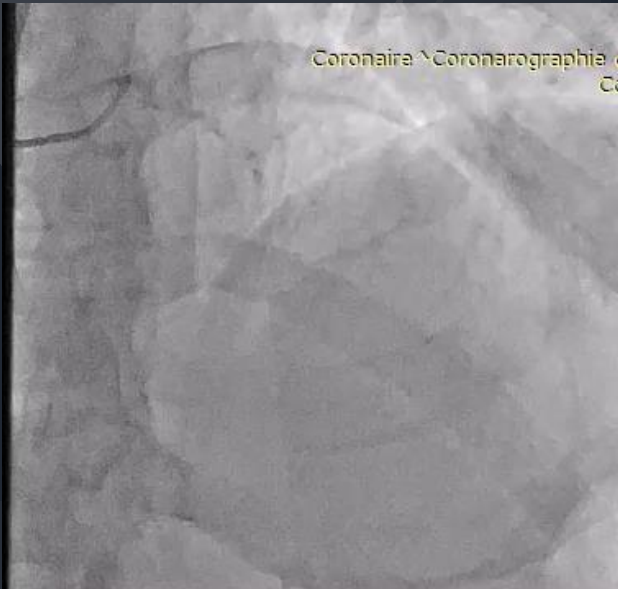Bois Bernard Private Hospital



Conflict of interest

- None

Diagnostic angio



70 yo male

Diabetes, GFR 96,
LVEF 66%

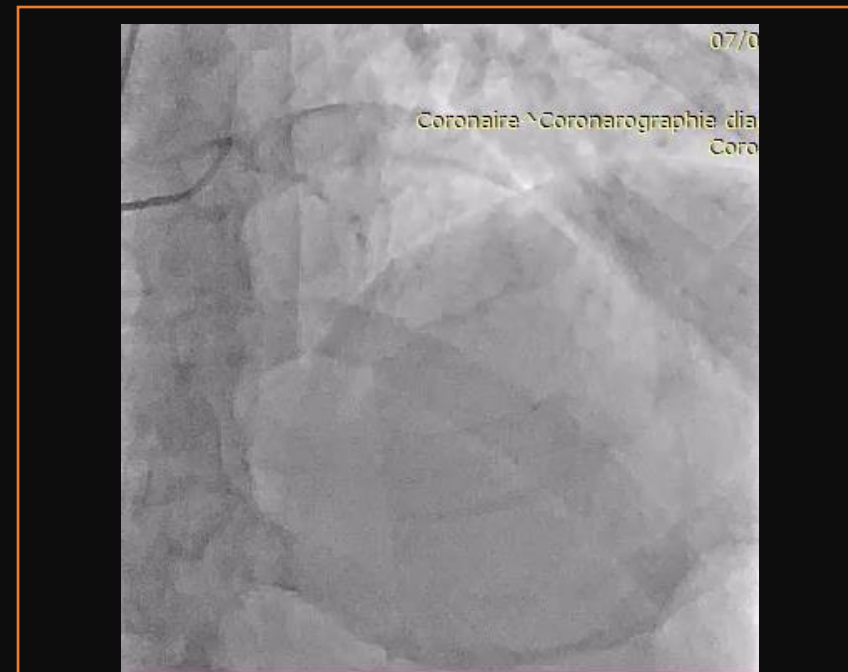CCS2, no WMA on
TTE

- Blunt
- 20 mm
- Calcified
- J-CTO 3
- Good landing zone, septal to RV branch

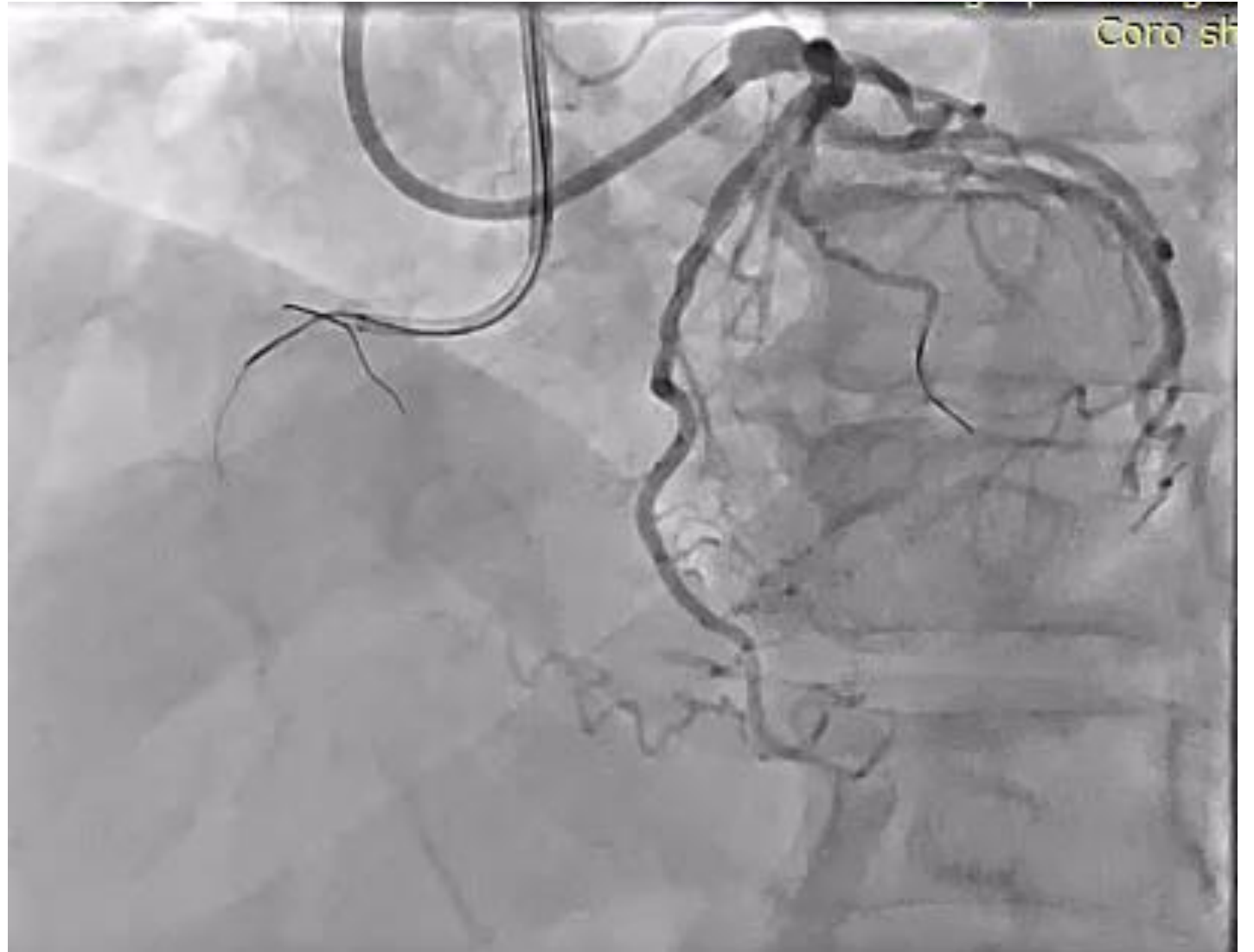1- AWE

2- ADR

3- Retro? Try CC0 septals

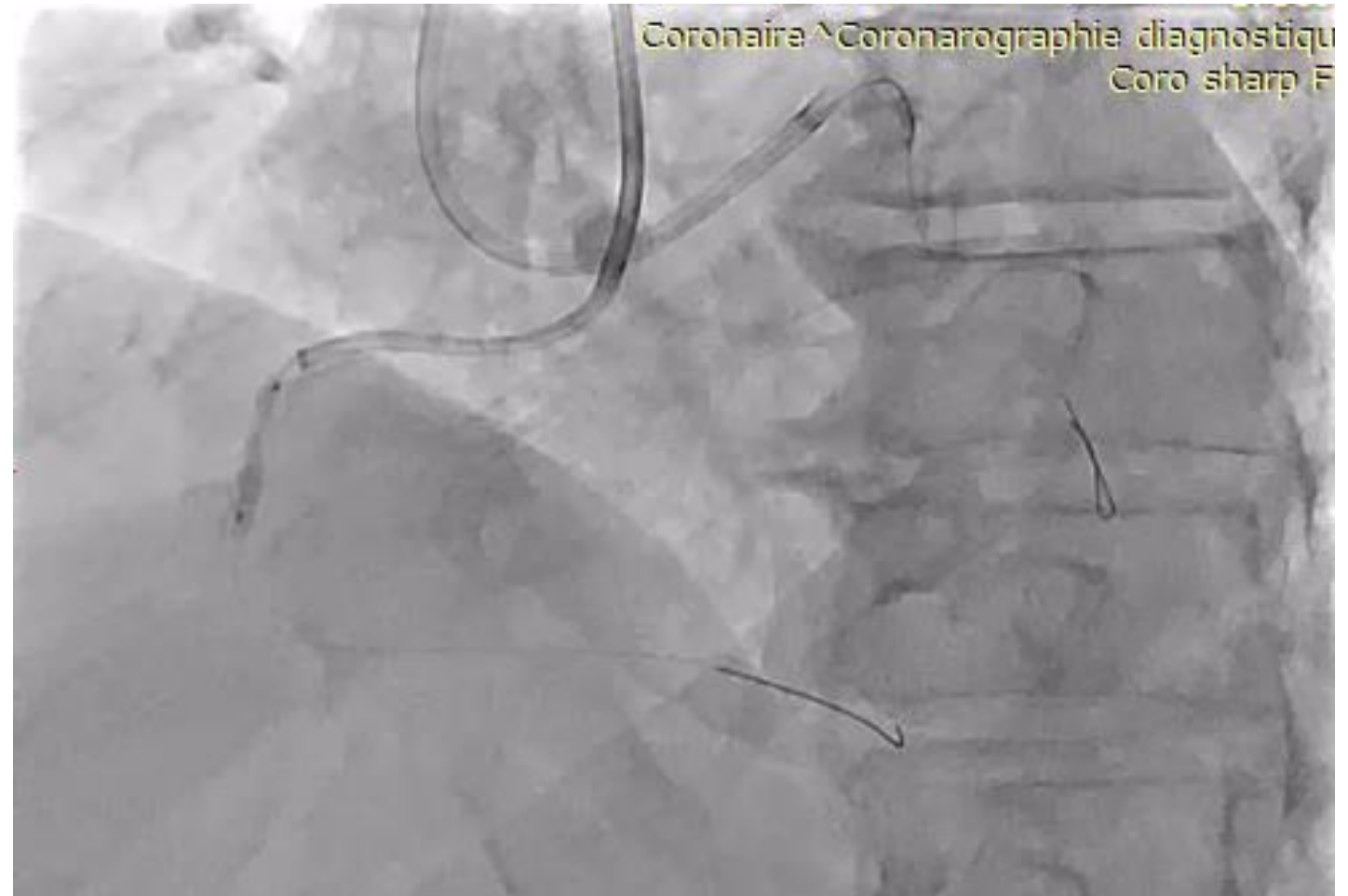

AL1 7F, Guide
extension Liquid
7F
Fielder XT easy
crossing
Corsair pro will
follow
Exchange for
Sion blue

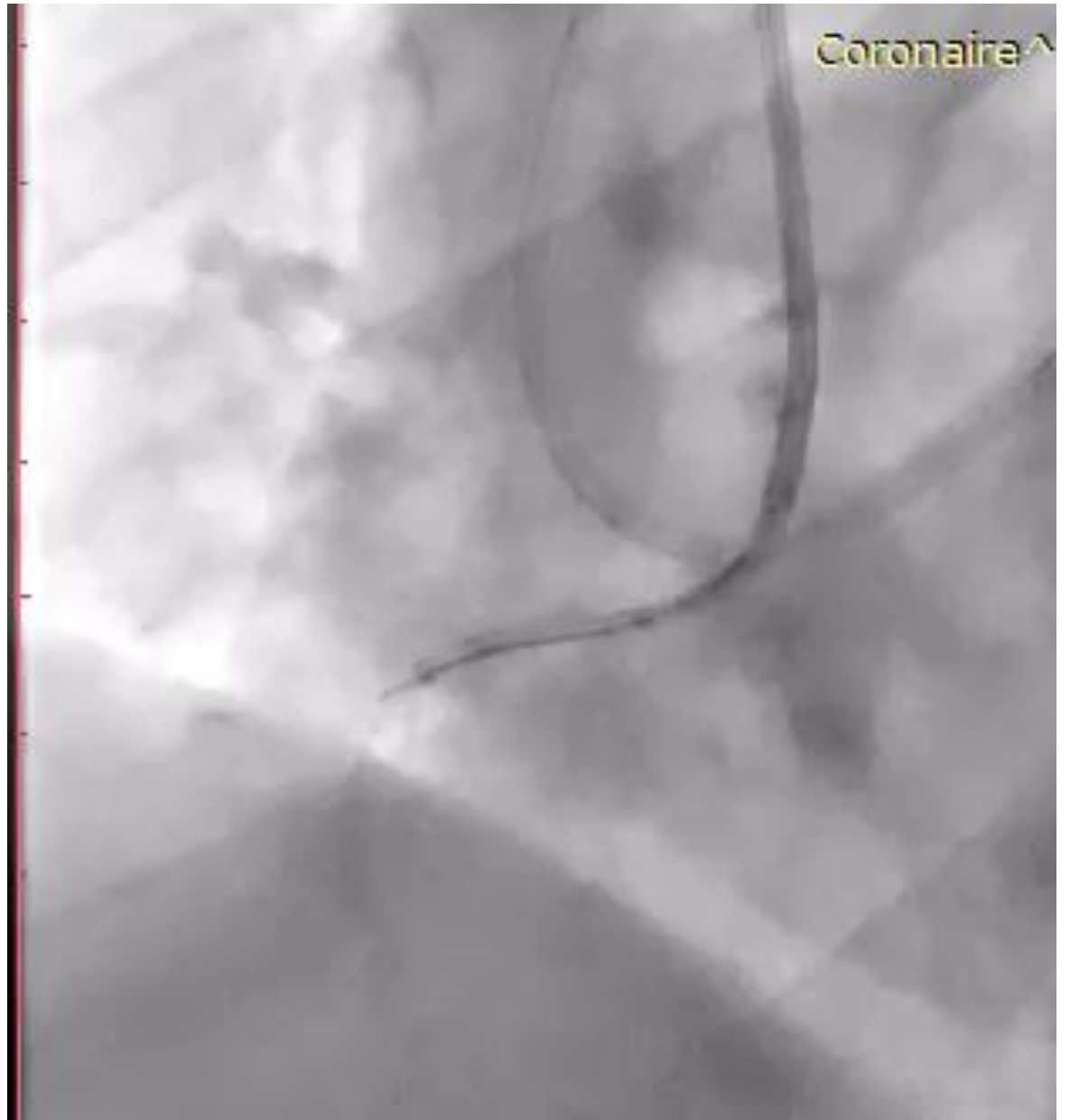

Semi
compliant :

Non compliant
Rupture 18
atm
Traped

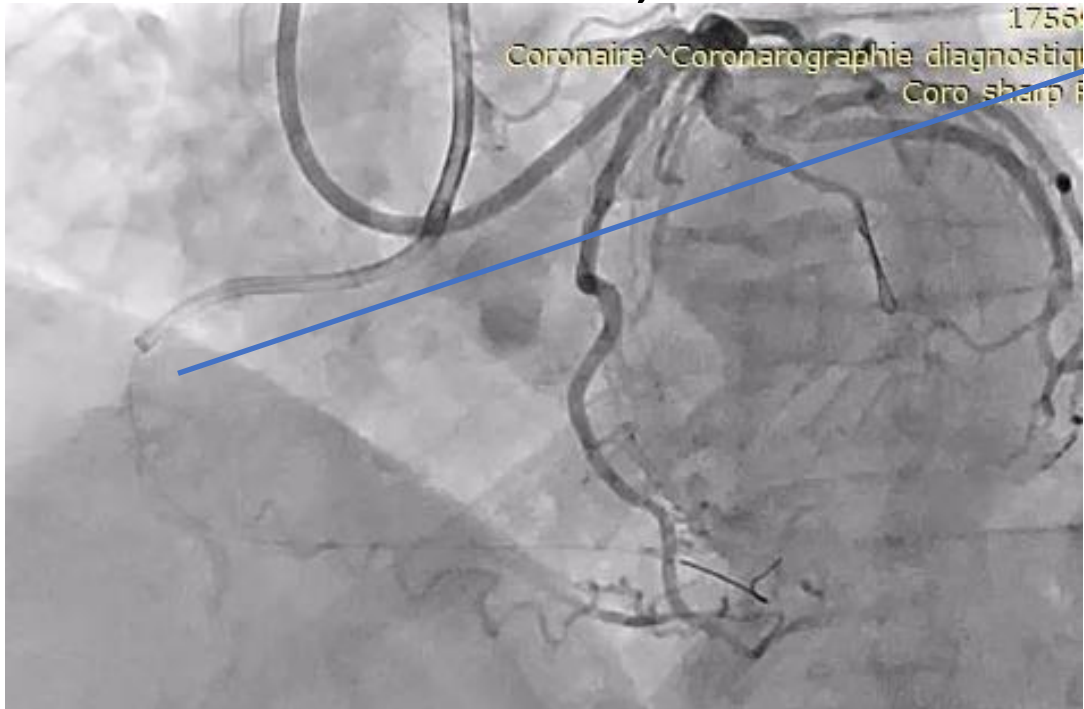


Balloon retrieval.
Pull hard. 2 markers
get inside, but...



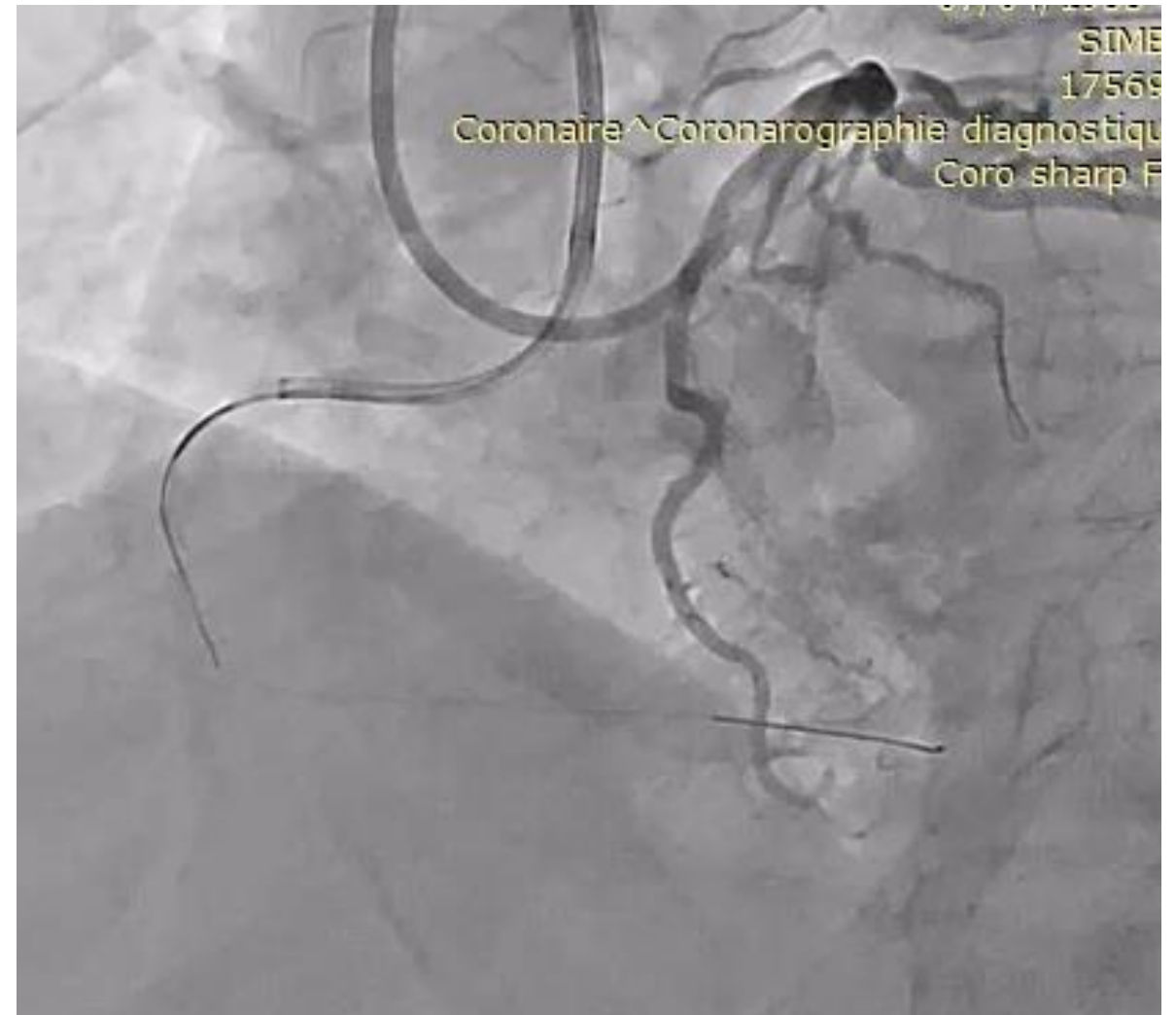Situation :

- Sion blue true to true
- Intra coronary trapped balloon membrane, 2 mm after extension, around wire

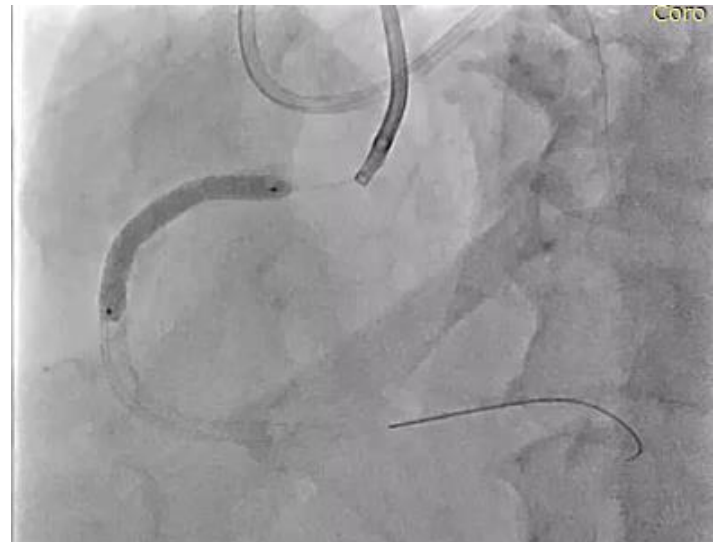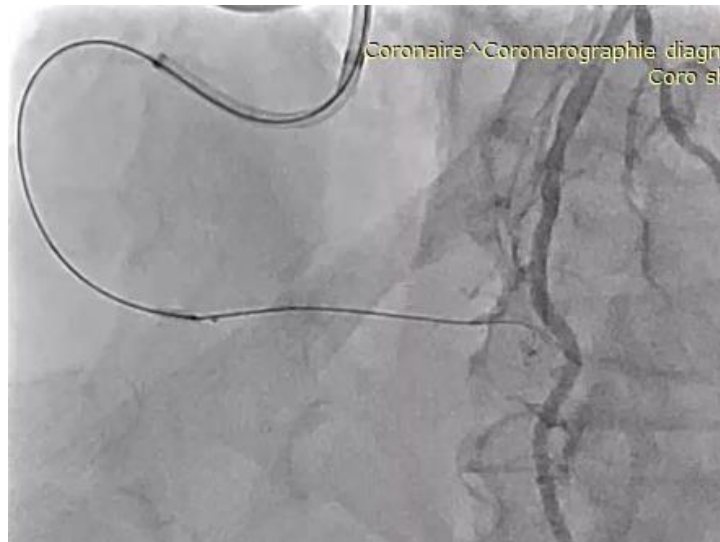

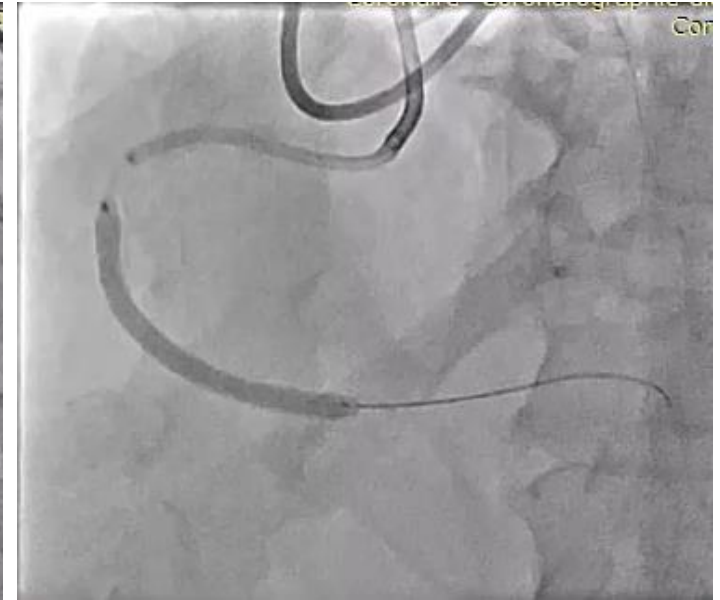
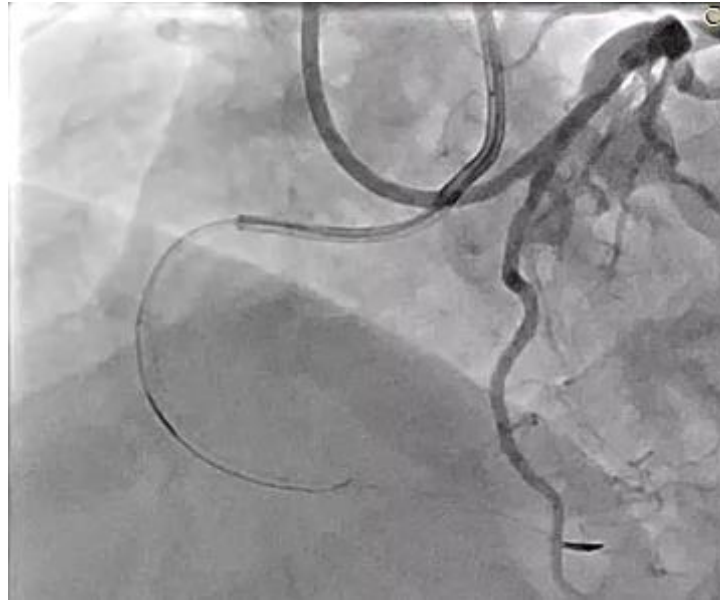On same wire : nothing crosses
(balloon membrane around
wire)

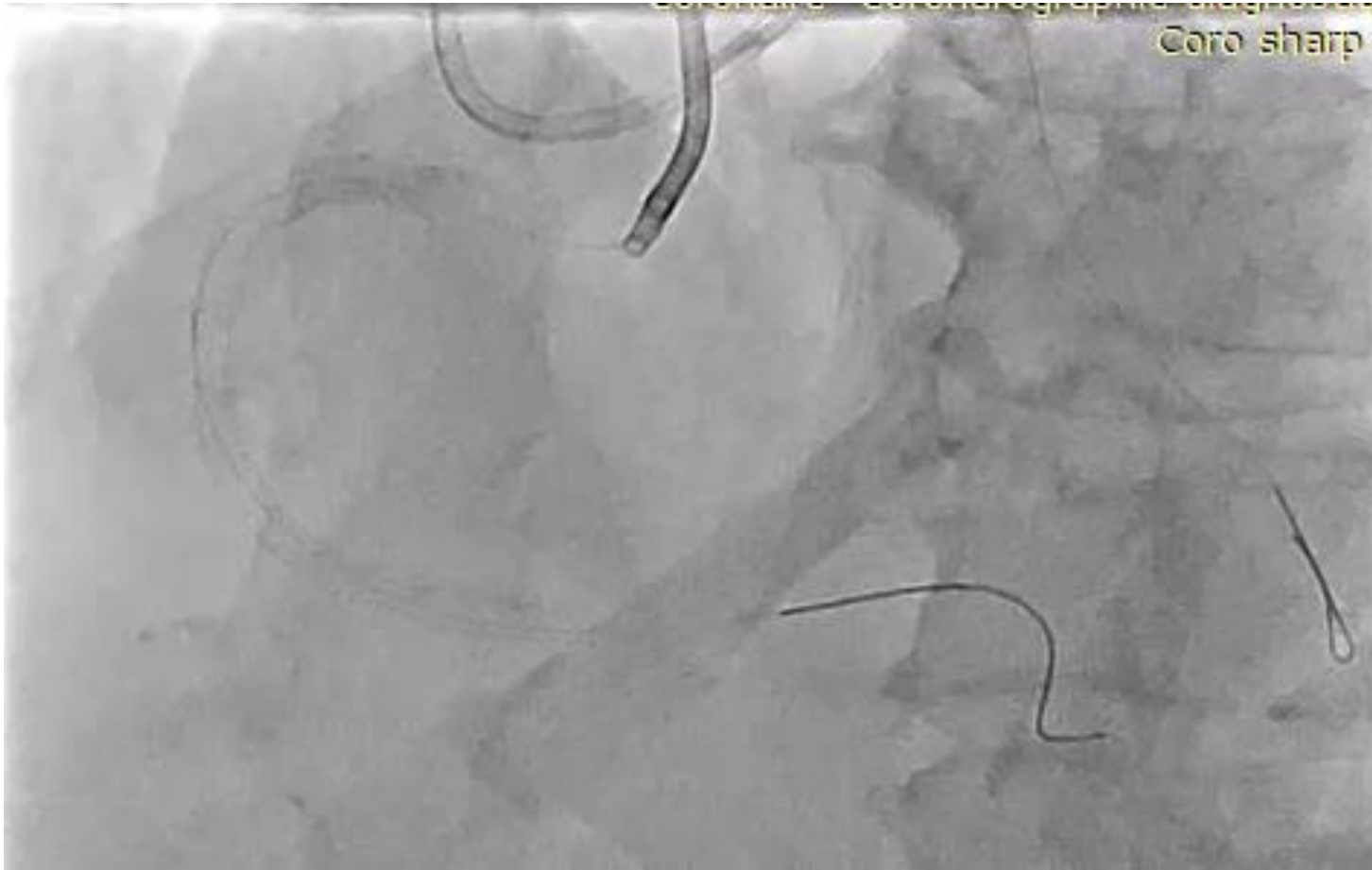New wire side to previous one :
fail



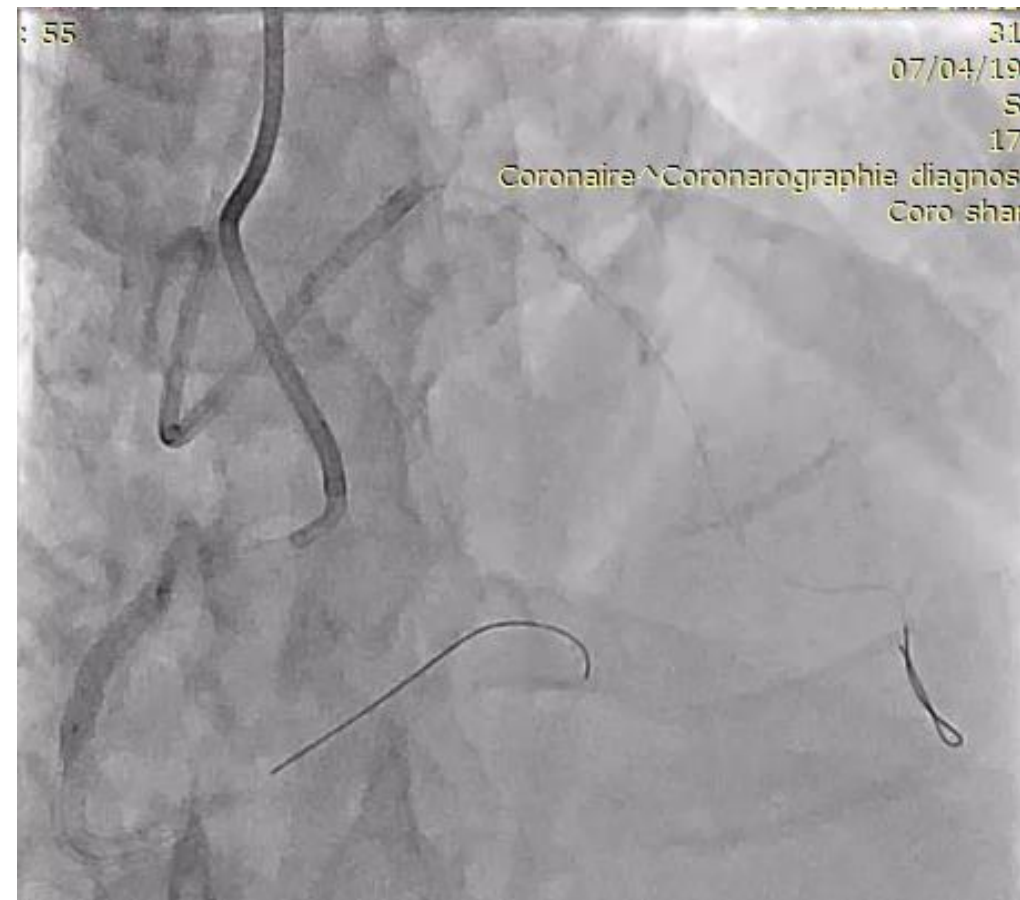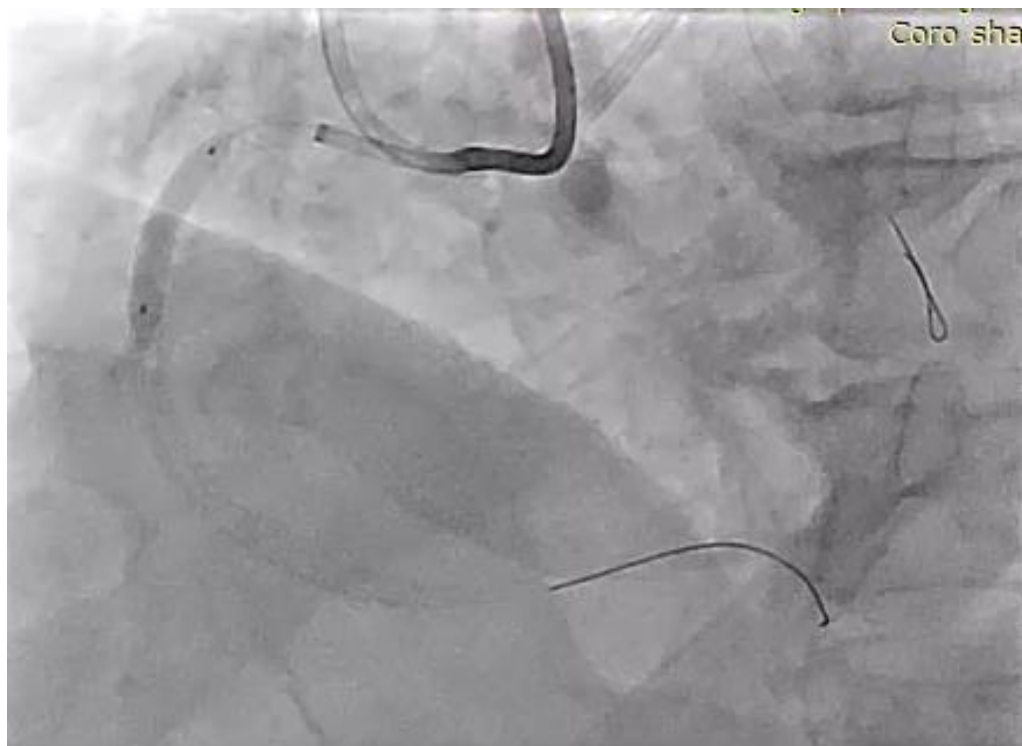Decision to go
ADR around
trapped
material



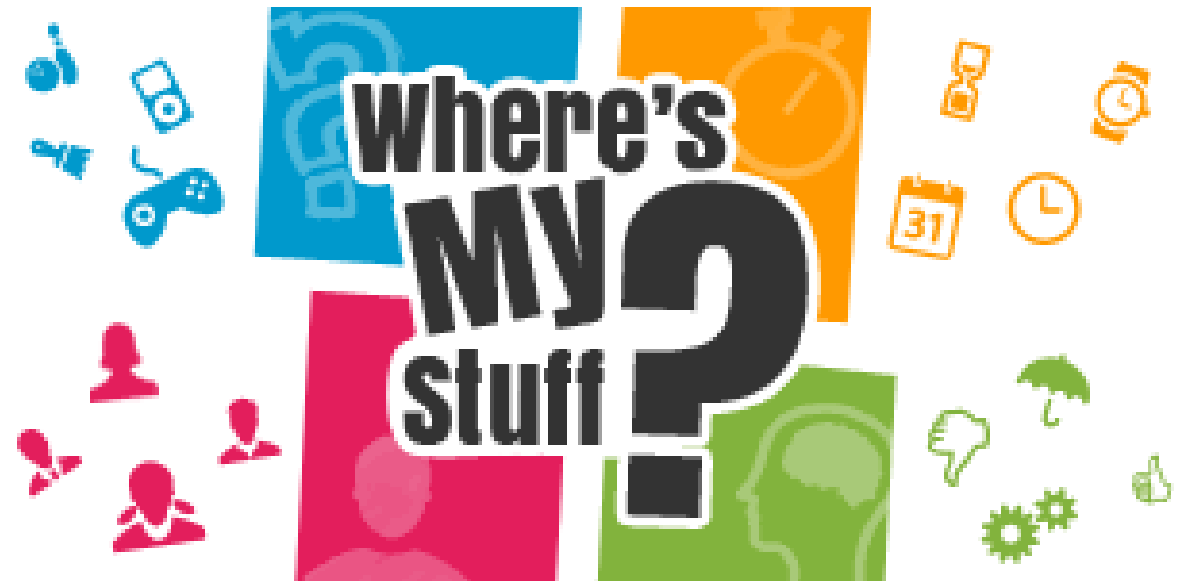Corona sharp



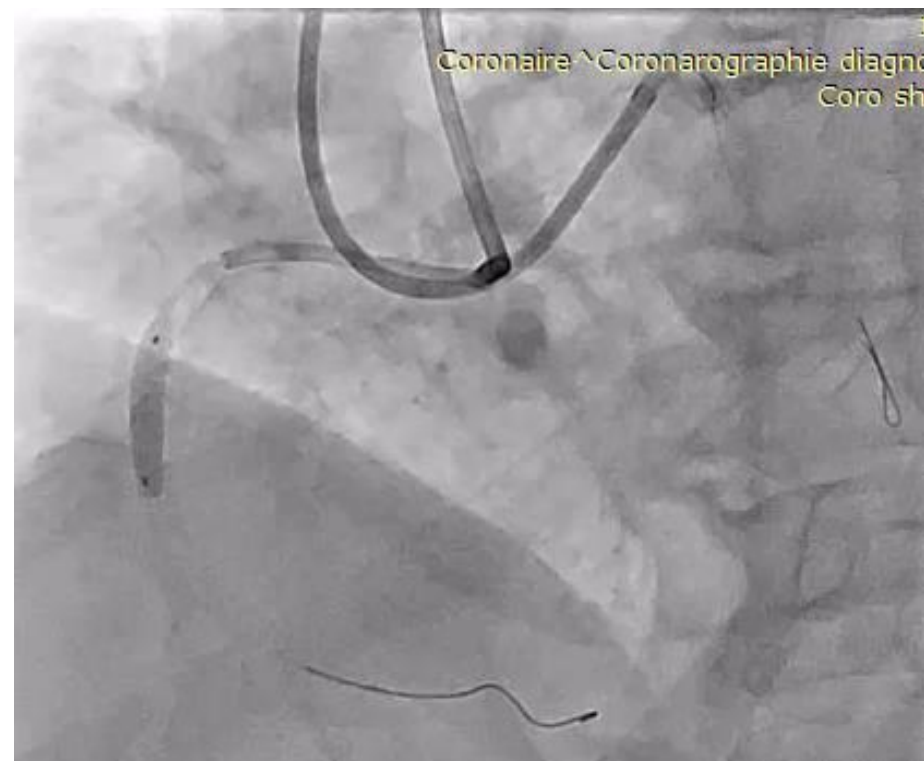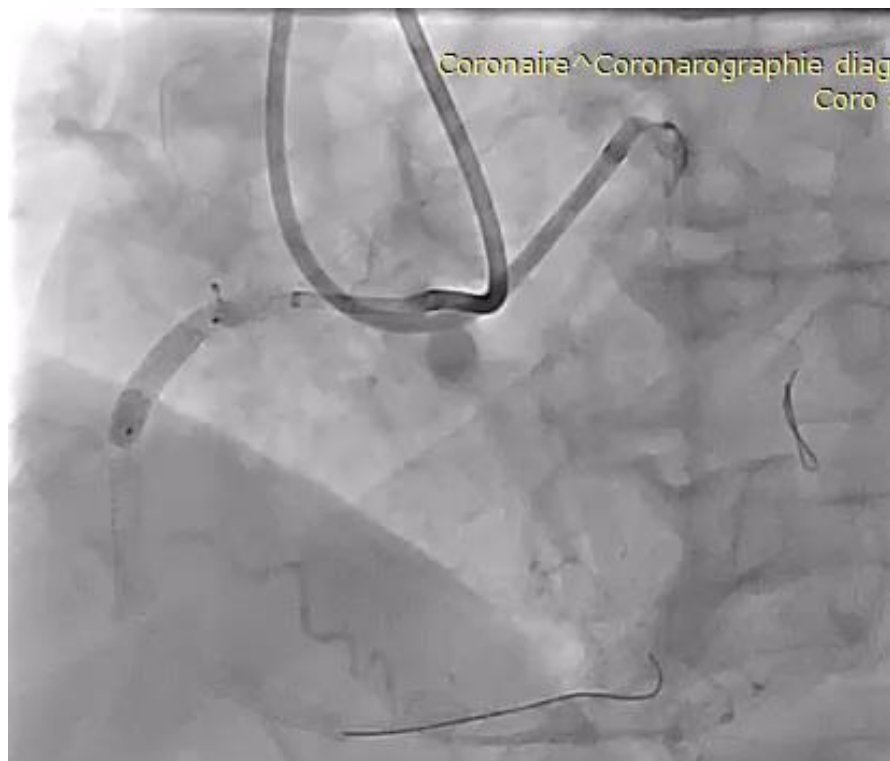Step 1 : prolonged balloon inflations



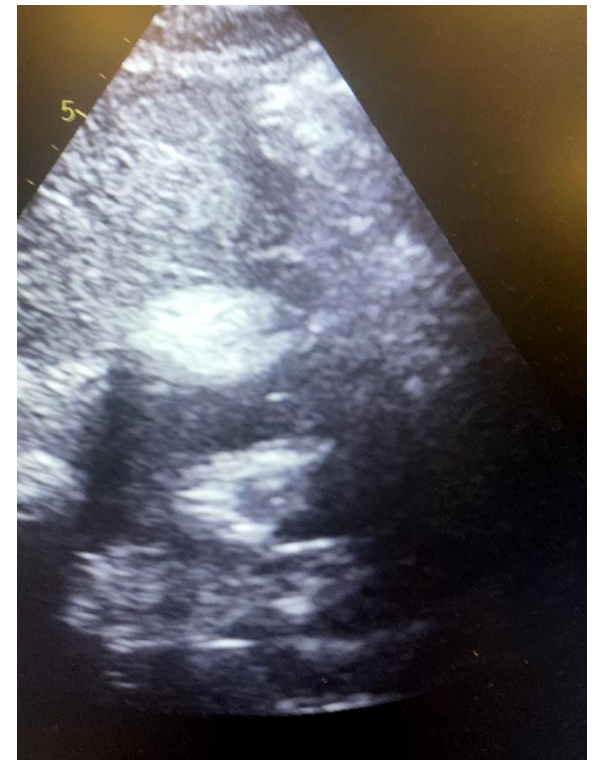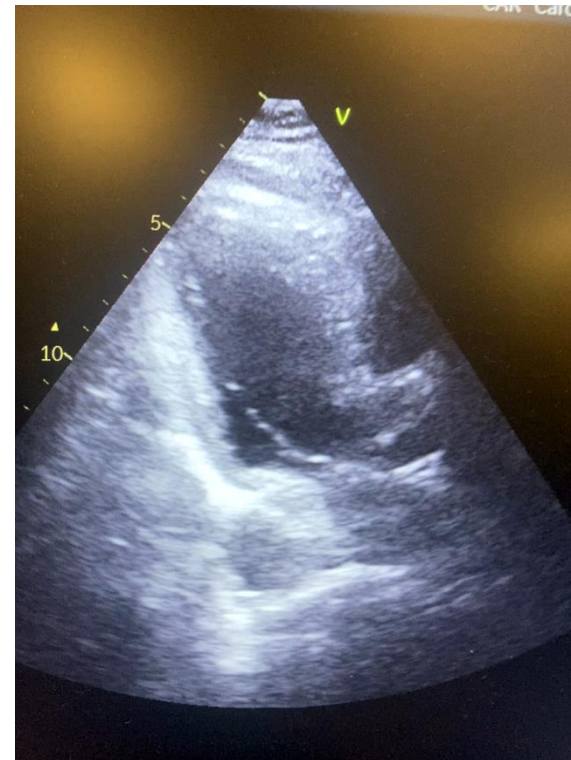
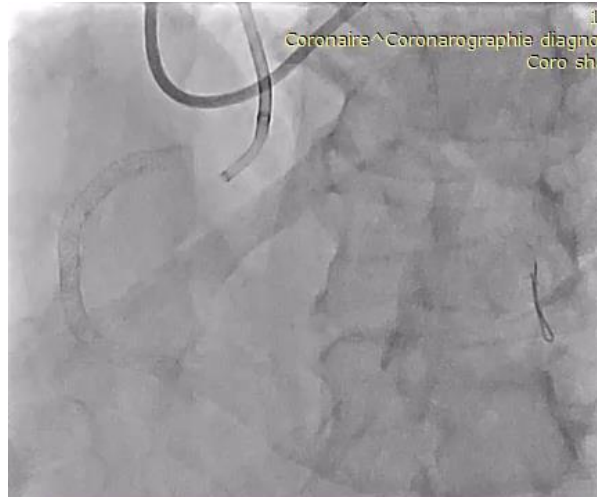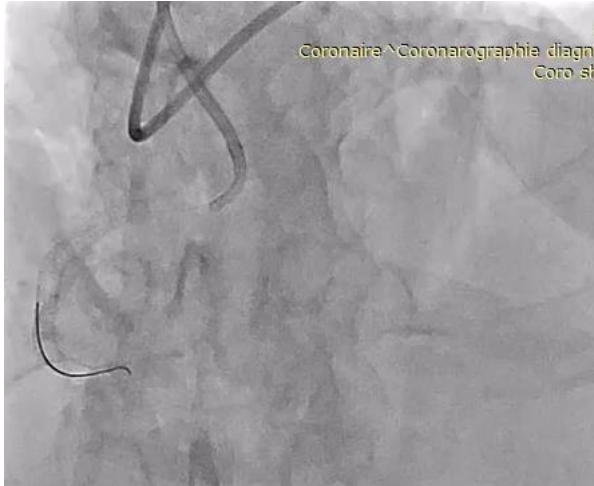Step 2 : covered stents



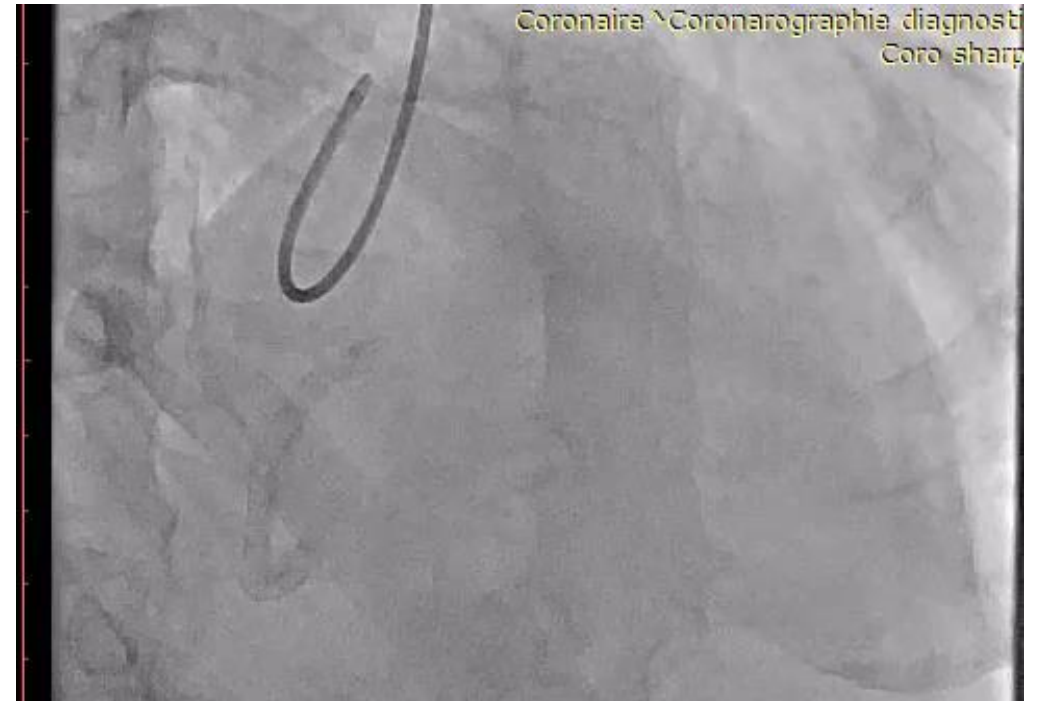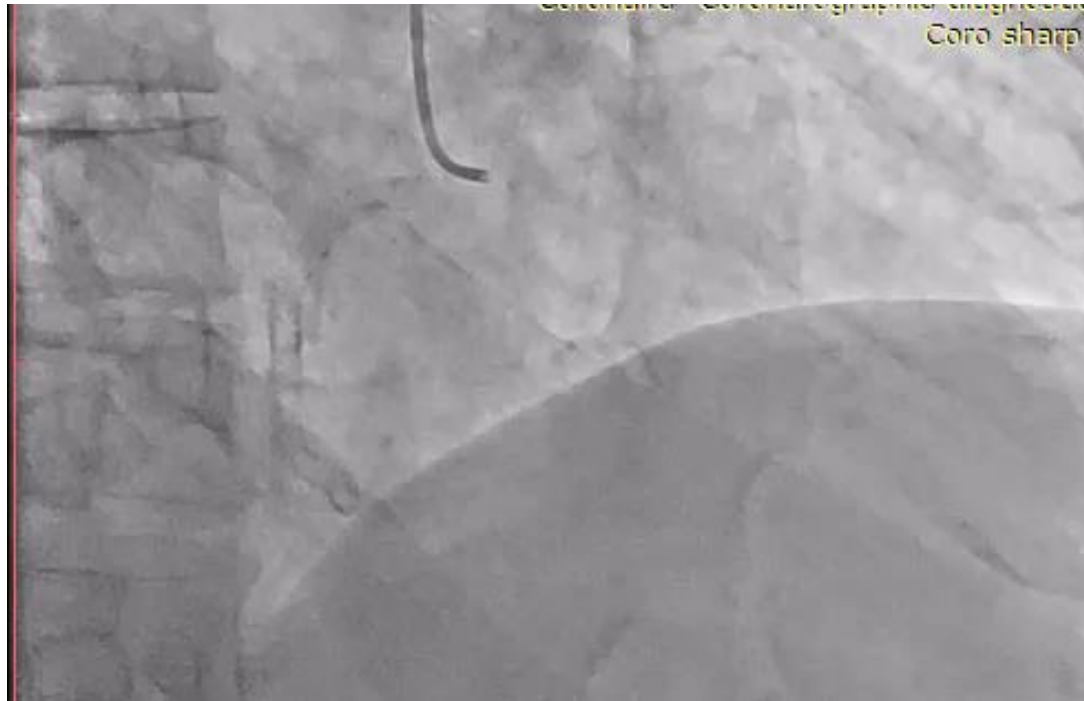Phew...



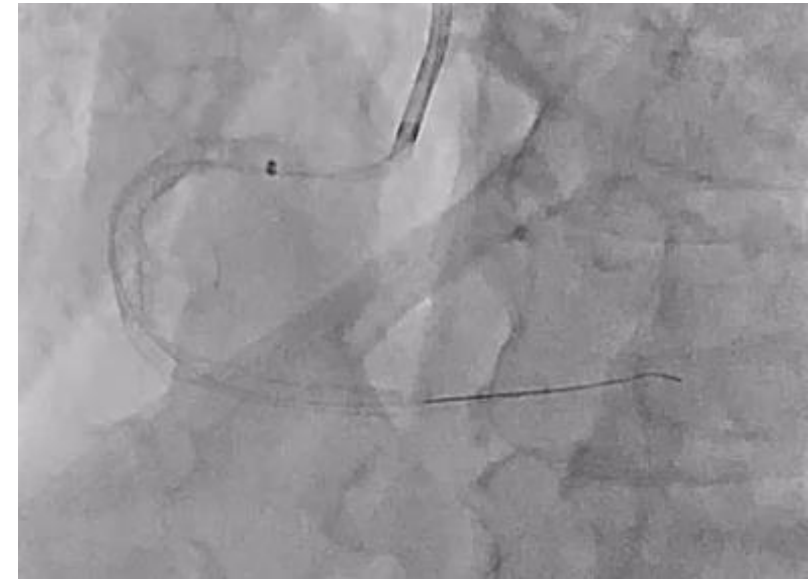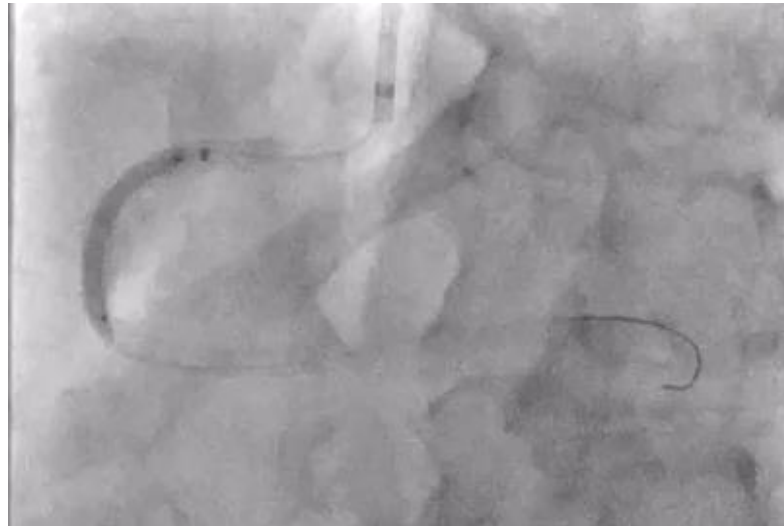
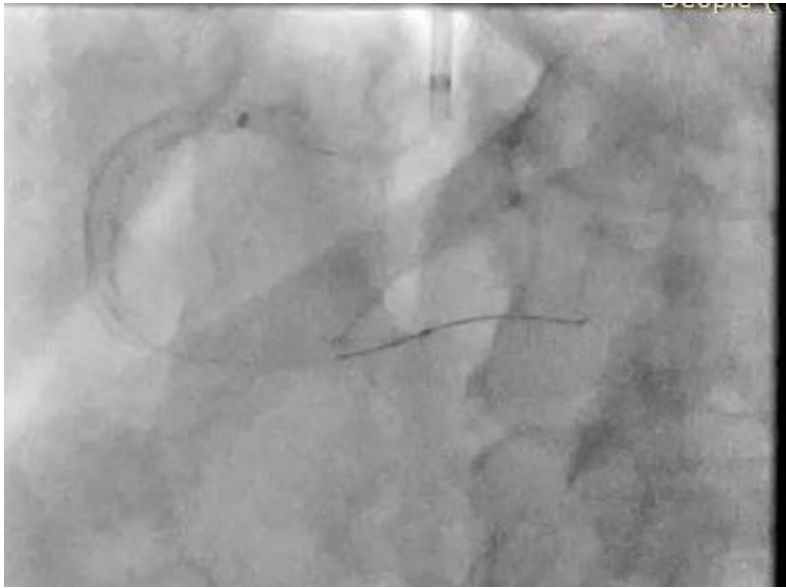Final result



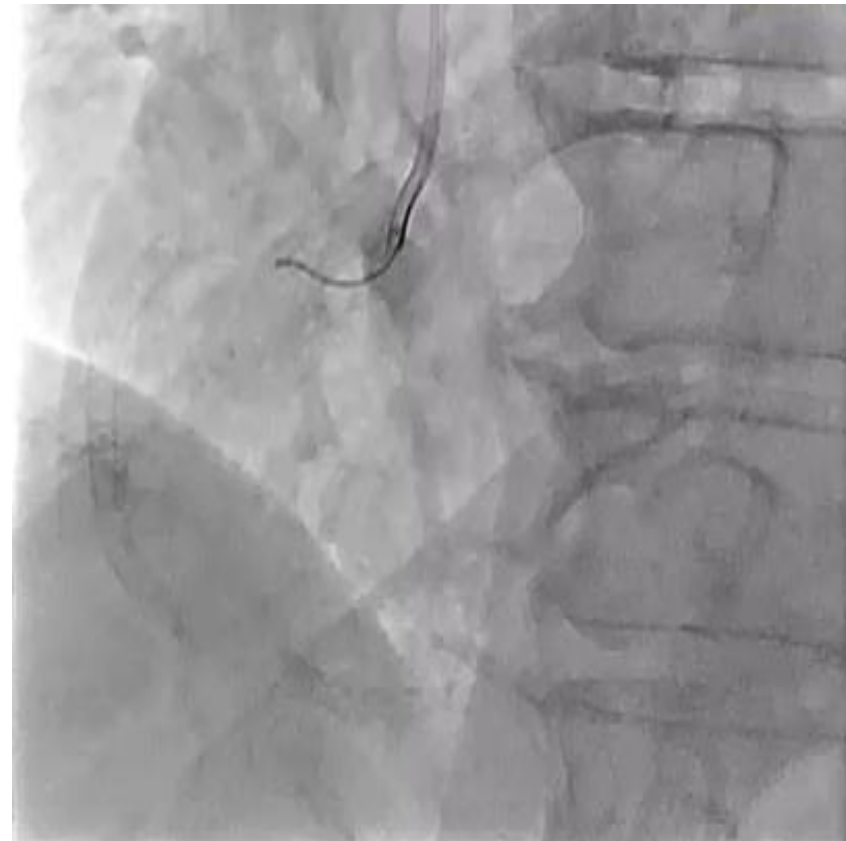
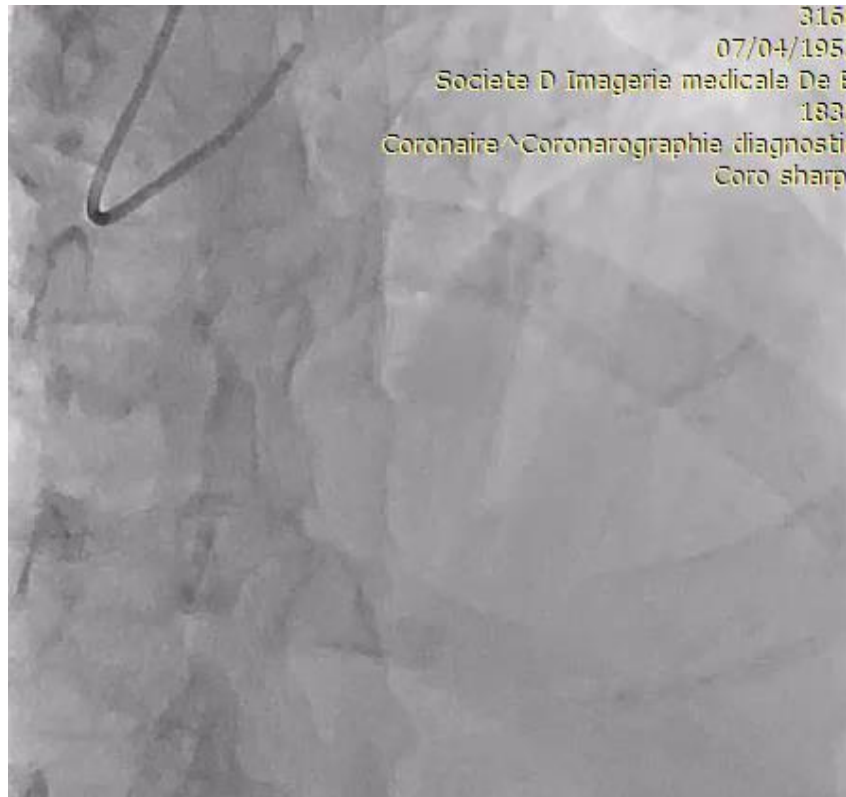1 month follow up



Ante (re)crossing, not that easy (Gladius, Finecross, Guideliner)



6 months later



- Early rota?
- Retrieve ballon?
- All CTO tools to treat complications
- Covered stents?

